Clinical Imaging 53 (2019) 35–42

Contents lists available at ScienceDirect

Clinical Imaging

journal homepage: www.elsevier.com/locate/clinimag

Musculoskeletal and Emergency Imaging

Ultrasound elastography in neuromuscular and movement disorders☆

Bryce Harmon, Michael Wells, David Park, Jing Gao*

Rocky Vista University, Ivins, UT, USA

ARTICLE INFO

Keywords:
Movement disorders
Neuromuscular disorders
Ultrasound
Ultrasound strain elastography
Shear wave elastography

ABSTRACT

The purpose of this review is to summarize main pathophysiology of neuromuscular and movement disorders, present published evidence of ultrasound elastography in the assessment of common neuromuscular and movement disorders, and discuss what role ultrasound elastography modality can play in respect to neuromuscular and movement disorders.

1. Introduction

Neuromuscular and movement disorders include a wide range of diseases and conditions that manifest as abnormal muscle movement, most commonly caused by disease in the central or peripheral nervous system, muscle, or both. Abnormal and impaired functioning of the musculoskeletal system can be very debilitating. Like a patient suffering from post-stroke spasticity, these conditions can severely affect the quality of life and normal daily activities [1].

Deenen and colleagues combined the prevalence rates of 24 different neuromuscular diseases that had been studied for prevalence and found that altogether they affect up to 160/100,000 individuals [2]. Wenning and colleagues found that common movement disorders have a prevalence of 28.0% in people aged 50–89 and that frequency increases with age as they reported that 51.3% of people aged 80–89 suffer from a movement disorder [3]. Ma and colleagues disclosed that in the US stroke has a prevalence of 6.8 million adults and Multiple Sclerosis (MS) has a prevalence of 400,000 [4]. Another disease included in our review, Parkinson's disease can affect up to 300/100,000 individuals worldwide [2]. It has been reported that 4.9 billion dollars is spent on Parkinson's disease yearly with an annual increase of 0.3% and 4.4 billion was spent on multiple sclerosis yearly with an annual increase of 2.0% [5]. Larkindale and colleagues found that in the U.S the annual cost of Myotonic Dystrophy (DM), Duchenne Muscular Dystrophy (DMD) and Amyotrophic Lateral Sclerosis (ALS) is $448 million, $787 million, and $1023 million, respectively [6].

Skeletal muscle is organized in a hierarchical structure of actin, myosin, and titin which makes fibers, fascicles, and muscles; this structure is critical as these pieces undergo complex interactions to determine the mechanical properties (stiffness) and function of the muscle [7]. Skeletal muscle contracts through stimulation by the alpha motor neuron which triggers the muscle to contract [8]. The neuromuscular system relies on sensory input from the muscle spindle to measure the length and velocity of the muscle as well as innervation from gamma motor neurons that keep the muscle spindle tight, so it is sensitive to stretch during all phases of contraction and relaxation [9]. Spastic hypertonia can result from increased motor neuron excitability when the responsiveness of muscles to passive stretch or the mechanical properties of muscle are altered [10].

There are quantitative and qualitative tools used to characterize the mechanical properties of musculoskeletal tissue. However, quantitative tools, such as dynamometry can be very complex, and qualitative methods such as palpation, the Modified Ashworth scale (MAS) or manual muscle testing [11] can be imprecise. Magnetic resonance imaging (MRI) and ultrasound are commonly used non-invasive tools to assess the macroscopic structure of muscle. However, the cost of a MRI is much higher than an ultrasound. A biopsy can provide critical information about the microscopic structure of the muscle, but it is invasive and is not routinely applied for the assessment of neuromuscular diseases [12]. Although these physical exam and diagnostic tools are valuable, they do not provide information about the mechanical properties of muscle that affect its movement function [12]. Ideally, there would be a non-invasive way to measure and quantify the mechanical properties and dynamic functions of muscle to aid clinicians in the diagnosis, evaluation of progression, and monitoring of disease treatment and rehabilitation [13].

Ultrasound elastography (USE) is a technique that can be used to ultrasonically quantify biological tissue stiffness by measuring the

☆ The authors have no conflict of interest to disclose.

* Corresponding author at: 255 East Center Street, Room: C286, Ivins, UT 84738, USA.
E-mail address: jgao@rvu.edu (J. Gao).

https://doi.org/10.1016/j.clinimag.2018.10.008
Received 6 May 2018; Received in revised form 30 September 2018; Accepted 5 October 2018

deformation or displacement of muscles that can be produced by external compression from the ultrasound transducer [14,15], focused ultrasound beams and acoustic waves [16,17], or applied vibration [14,18,19]. The ability of a tissue to deform or the amount of deformation is termed elasticity [20]. The more elastic a tissue is, the more it can deform. Conversely, the less elastic (stiff) a tissue is, the less it will deform [13]. Recently, USE has been made available on many commercial ultrasound scanners [21], thus making its clinical application more readily available. USE has been shown to be an effective tool in assessment, management, and research in a variety of pathological processes including, musculoskeletal functions, [13], liver fibrosis [22], arterial disease [23], breast masses [24], thyroid nodules [25], prostate cancer [26], cervical cancer [27], pancreatic masses [28], and tendon disorders [29] with low-cost.

The purpose of this review is to summarize the different USE modalities, present published evidence of USE in the assessment of neuromuscular and movement disorders, and discuss what role this low-cost ultrasound modality can play in respect to overcome the economic burden in neuromuscular and movement disorders management.

2. Ultrasound elastography

USE is an emerging modality with many techniques that are capable of quantifying tissue biomechanical properties associated with physiological conditions and pathological status of tissues [30]. There are different bioengineering methods used with ultrasound for determining the elasticity of tissue. These methods are categorized depending on the techniques used to deform the tissue, detect the deformation, and convert those details to an image [31,32]. The main USE techniques employed are strain elastography (SE), shear-wave elastography (SWE), acoustic radiation force imaging (ARFI), and transient elastography (TE) [33].

2.1. Ultrasound strain elastography

Ultrasound strain elastography is the most commonly used [7] and was the first USE technique available [34]. Ultrasound strain elastography is also referred to as compression elastography because it is based on the principle that strain is produced by compression of the tissue [14]. The compression is generally an exertive force generated by the ultrasound transducer (Fig. 1), thus deforming the tissue. This deformation is measured by comparing the distance of the deformed tissue to its initial distance (before the compression, Fig. 2) using the speckle tracking technique [35,36]. Strain is calculated using the equation Strain = (L1 − L0)/L0 (where L0 is the initial length of the muscle and L1 is the final length of the muscle) [35]. Hooke's law (which states that for relatively small deformation of an object, the displacement or size of the deformation is directly proportional to the deforming force or load) is a principal of Young's elastic modulus (E) and is the foundation of ultrasound strain elastography; if the compressive force on the tissue is equal throughout, then E (modulus of elasticity) = stress/strain [37].

Garra explains that strain is the change in tissue displacement vs. depth. Envision two points of an object, the top and the bottom (axial) [38]. When a compressive force is exerted on that object, a stiff object will be displaced or move as a whole unit away from the force, so the top and bottom will move an equal distance in respect to each other. When a compressive force is exerted on a soft object, the top will be displaced or move away from the force, but the bottom may not move at all or move less than the top. Hence, the strain is lower in stiffer tissues, as they deform less or do not deform at all. The strain is, therefore, higher in softer tissues, as they are deformed to a greater degree by the compressive force. For measurement purposes, these calculated strain values can be converted to a digital image that shows qualitatively the differences in strain by color or gray scale variations called an elastogram. This image can then be visualized either superimposed with the sonogram or displayed side by side [38]. The spectrum of colors in the elastogram (Fig. 3) are usually exhibited as blue for hard tissues, red for soft tissues, and yellow/green for intermediate tissues [21,31].

Obtaining a quantitative measurement using ultrasound strain elastography requires Young's modulus as previously mentioned. Using Young's modulus necessitates quantification of the compressive force or stress applied to the tissue [12]. There have been attempts to place pressure sensors on the ultrasound transducer to quantify the applied stress, but this is difficult to do without compromising sonographic quality [38]. A semi-quantitative value for tissue strain can be determined by using a ratio of the strain measured in the region of interest compared to the strain measured in another region of the same image that is believed to be normal, circumventing the need for a direct measure of the compressive force [39,40]. For tissue strain estimated in compression elastography to be useful in a clinical setting, strain measured in a diseased region needs to be normalized by using a

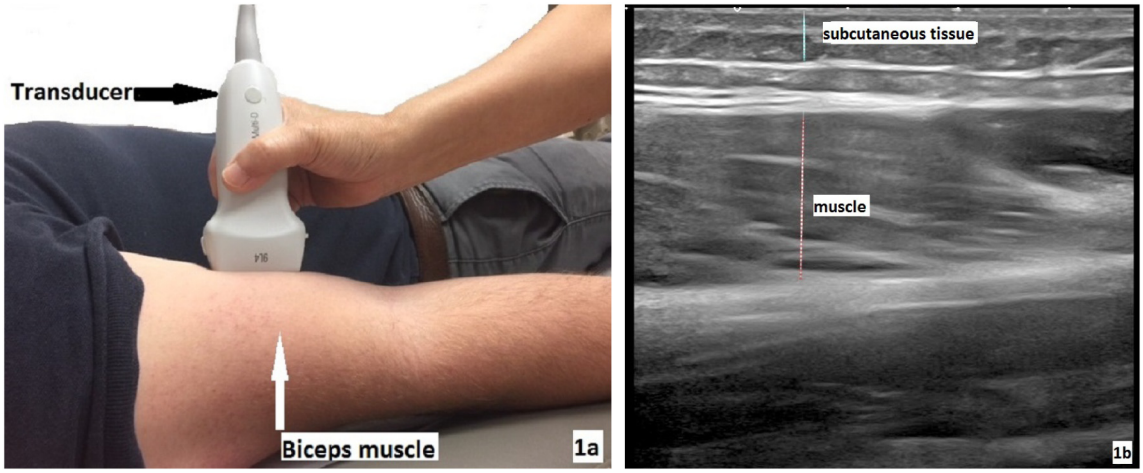

Fig. 1. a–b. A linear array transducer is commonly used to image skeletal muscles. The orientation of the transducer (black arrow) elongate muscle fiber (white arrow, 1a) creates longitudinal section grayscale image of the muscle (1b), which is suitable to assess muscle mechanical properties using ultrasound elastography. In ultrasound strain elastography, muscle axial strain is the axial deformation in the muscle (red dotted line) and the reference strain is the axial deformation in subcutaneous soft tissue (cyan dotted line, 1b). Strain ratio is defined as the muscle strain divided by reference strain. (For interpretation of the references to color in this figure legend, the reader is referred to the web version of this article.)

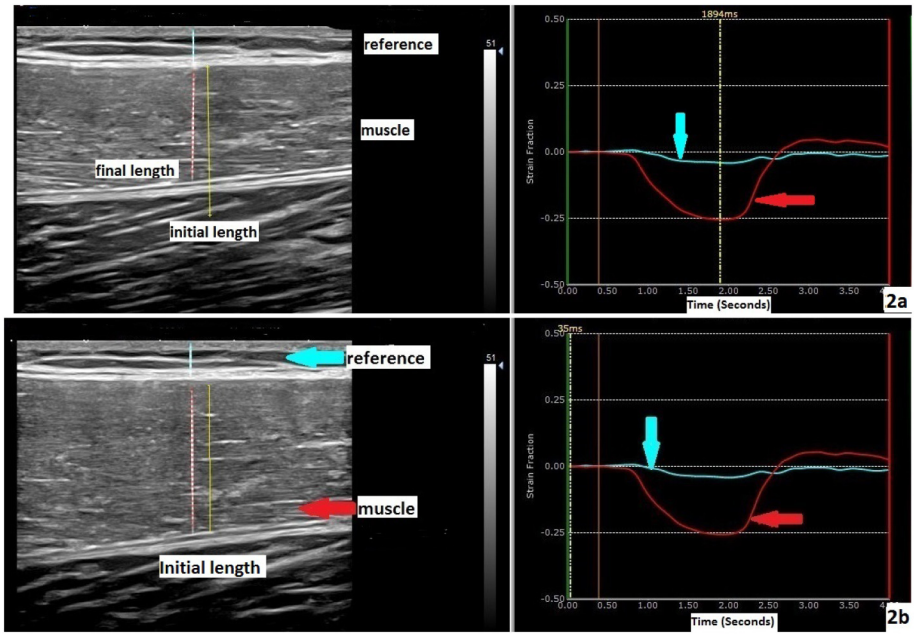

Fig. 2. a–b. Muscle axial deformation is produced by external compression using ultrasound transducer and estimated using 2-D speckle tracking software. The muscle axial strain (red curve) is a fraction of the final length of the muscle (red dotted line, 2a) to the initial length of the muscle (red dotted line, 2b). The reference axial strain (cyan dotted line and curve) is a fraction of the final length of the reference tissue to the initial length of the reference tissue. Strain ratio is defined as a muscle strain divided by a reference strain. The yellow solid line in grayscale images (2a and 2b) is the measure of the initial length of the muscle. (For interpretation of the references to color in this figure legend, the reader is referred to the web version of this article.)

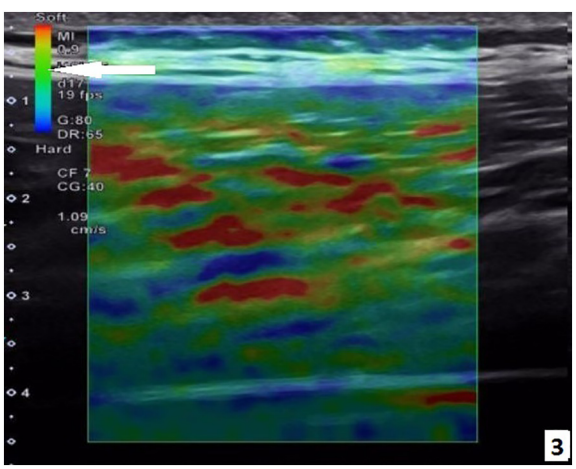

Fig. 3. A color-coded map represents the tissue hardness with qualitative color scales (white arrow). The red color represents tissue soft whereas the blue color represents tissue hard in ultrasound strain image. (For interpretation of the references to color in this figure legend, the reader is referred to the web version of this article.)

reference strain measured in relative normal tissue (Figs. 1 and 2). This normalized measure is called the strain ratio [41]. Elastograms should be used from the middle of the compression cycle, as they are inaccurate at the beginning or end, and repeated multiple times to ensure accuracy [42]. Speckle tracking with correlation coefficient method is commonly used to estimate the strain (deformation or displacement) in tissue motion frame by frame in real time ultrasound cine loops (Fig. 4). However, ultrasound strain elastography is suboptimal for imaging locations where it is difficult to apply equal levels of compression because of surrounding tissue or structures that may hinder the ability to apply equal pressure [43].

Measuring tissue strain with ultrasonography can be challenging. However, new software has been developed that provides real-time information on how much compressive force is being applied during an ultrasound scan. This is very useful in addressing the issue of ensuring equal levels of compression are applied for each scan [37]. There are also internal physiologic sources, like breathing and cardiac motion, that can exert a stress on surrounding tissues. These physiologic stressors are difficult to account for and can confound strain measurements [44]. Ultrasound strain elastography may also give suboptimal results when measuring soft inclusions that are surrounded by stiffer tissue. The surrounding stiffer tissue does not allow the softer tissue to deform as it traditionally would from the compressive force and, therefore, can mask the true elasticity of the tissue [45]. Due to the various techniques that are used to analyze the data in ultrasound strain elastography, there are potential uncertainties involved when comparing results across studies, interpreting data, and study reproducibility [37]. Also, technical challenges in performing strain elastography include insufficient compressive force, operator or patient induced out-of-plane motion, and operator–dependent skill [46].

2.2. Acoustic radiation force impulse (ARFI)

Acoustic radiation force impulse (ARFI) is another ultrasound imaging technique capable of measuring the displacement of a tissue as a force is applied to the tissue. However, in ARFI the force does not come from manual compression by the operator, but from a push pulse generated by the ultrasound transducer beam, and like SE, softer tissues are displaced more than stiffer tissues [12]. The tissue either absorbs or reflects the momentum from the wave, thus causing a displacement [47], which then can be measured by rapid imaging ultrasound pulse echoes and displayed as a qualitative elastogram [7], Comparing with ultrasound strain elastography, ARFI based elastography is less dependent on the skills of the operator as push pulses are consistent when compared to free-hand compression using the ultrasound transducer [15]. ARFI based ultrasound elastography has been used in clinical settings broadly. Quality of shear wave estimation can be assessed using shear wave quality map (Fig. 5a) or shear wave propagation map (Fig. 5b) depending on the technical design by ultrasound manufactures. Unfortunately, this technique is not reliable when used on structures that are deeper than 6 cm because the pulses cannot displace tissue adequately beyond that depth [38]. Another disadvantage to ARFI is the high amount of energy created from the waves that is transferred to the transducer and tissue. This increase in energy can cause overheating of both the transducer and tissue, possibly limiting the number of scans that can be completed [12]. AFRI's greatest advantage is the ease of use for clinical application since the system uses a single transducer to apply the force and measure results. It also has great feasibility for real-time imaging because the pulse application

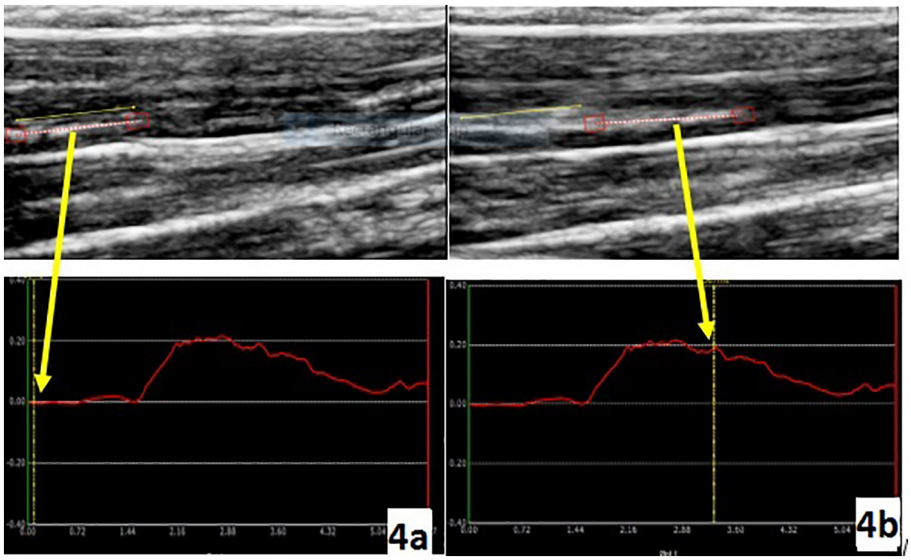

Fig. 4. a–b. Longitudinal dynamic displacement of the biceps brachii muscle cine loop is captured during passive elbow movement. Using 2-D speckle tracking, muscle lengthening (elbow extension) is estimated using correlation coefficient method. Again, longitudinal strain is the fraction of the final length of muscle displacement (yellow arrow, strain = 0.28, 4b) to the initial length of the muscle prior to the displacement (yellow arrow, strain = 0, 4a). (For interpretation of the references to color in this figure legend, the reader is referred to the web version of this article.)

lasts less than one millisecond [47].

2.3. Shear-wave elastography

Shear-wave elastography (SWE) is a method used to quantify the mechanical properties of tissue [48] by measuring waves that travel laterally and perpendicularly to the emitted acoustic ultrasound waves [49]. These waves, called shear waves, are generated from a series of compressional ultrasound pulses that displace the tissue (similar to ARFI); as the tissue is displaced, a shear wave is created that propagates away from the pulse beam [50]. As the shear waves propagate along the tissue, they are tracked by another low pulse wave emitted by the ultrasound transducer [38]. Shear waves are similar to ripples created when a rock is thrown in a body of water. These waves are measured based on the principle that waves travel at higher speeds in stiffer tissues and lower speeds in softer tissues [51]. The velocity of the shear wave is measured algorithmically and used to calculate elasticity by way of Young's elastic modulus, using the equation $\mathbf{E = 3pc^2}$ (E is Young's elastic modulus, c is the shear wave velocity (SWV), p is tissue density) [52]. An image is generated that is qualitative and quantitative, qualitatively showing an elastogram with color scale like previously mentioned and quantitatively showing the SWV (meters per second) corresponding to the colors on the chart [38].

SWE is a feasible tool to measure slow muscle contractions clinically because it can generate elastograms at a speed of 1 Hz [7]. Because ultrasound push beams must travel certain depths before a shear wave can be produced, caution must be taken when measuring structures that may be too superficial [37]. However, the accuracy and reliability of SWE decrease as the depth increases [38]. Further, shear waves may not be measured accurately if the tissue being measured is too heterogeneous due to the creation of malformed shear waves and tissue attenuation causes the shear waves to be too weak for accurate measurements [38]. The accuracy of SWE in the assessment of anisotropic tissue [53,54] and the relationship between the value of SWV and age or gender [55] must also be considered and need to be studied further to determine how SWE measurements could be impacted. However, as reported, this technique has proven to be useful in the assessment of the mechanical properties of skeletal muscle in physiologic [55,56] and pathologic [57] conditions.

2.4. Transient elastography

Transient elastography (TE) also measures the velocity of shear waves within the tissue. However, in this modality, the shear waves are generated by a vibrator on the ultrasound transducer. This vibrator acts like a rapid piston on the surface of the skin by providing small repetitive impacts on the tissue [15]. Like previously mentioned with SWE, the shear waves are measured by pulse-echo acquisitions as they propagate through the tissue and stiffness is calculated based on their speed [58]. The scanning lasts about 5–10 min as patients are scanned a minimum of 8–10 times [7]. At least 60% of those scans must be classified as "successful" from data collected by the ultrasound machine [58]. Once again, the elasticity is calculated by Young's modulus after the SWV has been determined. The main limitation of this method is that it does not produce conventional B-mode ultrasound images because it uses a single-element transducer instead of an array multi-element ultrasound transducer [12]. Therefore, the region of SWV sampling may not be the same as what the operator expected. Unlike

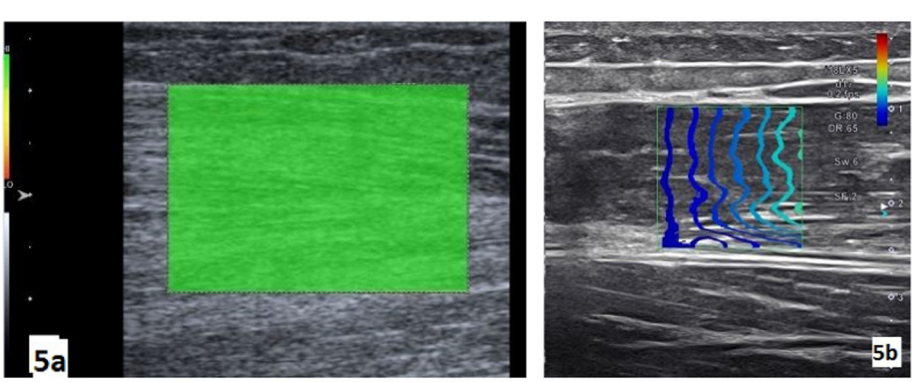

Fig. 5. a–b. The quality of shear wave speed estimation is evaluated using shear wave quality map (5a, Acuson S3000, Siemens Medical Solutions) in ARFI based shear wave elastography or using shear wave propagation map (5b, Aplio i800, Canon Medical System) in shear wave elastography. Homogeneous green (5a) and parallel lines perpendicular to push pulse (5b) indicate a reliable quality of shear wave speed estimation in the region of interest to measure sheave wave velocity and shear modulus. (For interpretation of the references to color in this figure legend, the reader is referred to the web version of this article.)

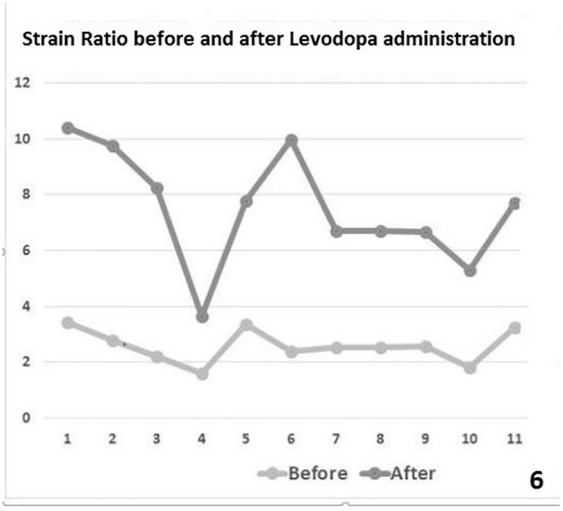

Fig. 6. Ultrasound strain imaging of the biceps brachii muscle was performed in patients who underwent acute Levodopa challenge test for the diagnosis of Parkinson's disease (PD). The strain ratio of muscle to reference significantly increased after administrating Levodopa compared with that before administrating Levodopa, which reflects the response of the rigid muscle to Levodopa. The report suggests that ultrasound strain imaging is feasible to assess muscle rigidity in Parkinson's disease. Before, before Levodopa administration; after, after Levodopa administration.

SWE, overheating is not an issue with TE since superficial physical thumps are used to generate the stress instead of push pulses [15]. However, TE measurements can be unreliable in up to 20% of patients, and it should not be used in patients with ascites [59] or other conditions with fluid build-up as shear waves cannot propagate through fluid [15].

3. Ultrasound elastography for examining neuromuscular disorders

3.1. Myositis

Botar-Jid and colleagues used USE to study patients with inflammatory myopathies, a group of disorders that include, but is not limited to inclusion body myositis, polymyositis, dermatomyositis, and even thyroid disorders [60]. These diseases are distinguished by compromised muscle structure and are diagnosed from a combination of clinical presentation, lab work, and biopsy. Common diagnostic lab tests utilized include creatinine kinase (CK), lactate dehydrogenase (LDH), erythrocyte sedimentation rate (ESR), C reactive protein (CRP), and anti-nuclear antibodies (ANA). The study showed that USE elastogram mapping of muscle directly correlates with CK, LDH, CRP, and ESR values [60]. The correlation was strongest with CK and LDH. These results could be because CK and LDH are more specific inflammatory markers for muscle, while ESR and CRP are general systemic inflammatory markers. This makes a strong case for the use of USE to help with inflammatory myopathy diagnosis when correlated with CK and LDH values. The information that USE provides about the structural changes of muscle also makes it useful for following disease evolution as well as response to therapy suggesting USE could be a useful diagnostic tool to aid in the morphological evaluation of muscles.

3.2. Cerebral palsy

Cerebral palsy (CP) is a condition that is caused by brain damage or brain malformation that affects the patients' ability to control muscle movement. While the brain damage normally does not progress, these patients can see a progression of their inability to control their muscles resulting from passive muscle stiffness or spasticity producing a progressive loss of passive joint range of motion (ROM) [11]. Rehabilitation efforts for these patients revolve around treating the muscle by strengthening, stretching, and reducing spasticity; thus, a method of quantitatively measuring muscle stiffness would be advantageous for evaluation in this patient population [11]. When measured with USE and compared to children without CP, Brandenburg and colleagues found that children with CP have significantly higher levels of muscle stiffness at 0, 10, and 20 degrees of plantar flexion with p-values of 0.001, 0.002, and 0.001, respectively [11]. Also, as a group, children with CP have more variability of muscle stiffness with different foot positions compared to children without CP. This finding is believed to be due to the common knowledge that muscle stiffness or spasticity in CP is on a spectrum [11]. As this study demonstrates, USE can be used clinically to measure muscle stiffness in children with CP and could potentially help diagnose as well as monitor progression and guide treatment in patients with CP [61]. Also, ARFI based USE was capable of demonstrating a difference in muscle stiffness in the medial gastrocnemius muscle (GCM) between children with CP and healthy controls, further supporting USE as a feasible imaging modality for the non-invasive assessment of contracting muscles in children with CP [62].

3.3. Parkinson's disease

Parkinson's disease (PD) is an idiopathic neurological condition caused by neurodegeneration, typically of the dopaminergic neurons in the substantia nigra, thus affecting the musculoskeletal system by causing a tremor, bradykinesia, rigidity, and gait instability. There is no cure for PD, but dopaminergic medications are used to treat symptoms. PD is largely a clinical diagnosis based on the patient's medical history and physical exam findings focusing on four cardinal features: bradykinesia, tremor, rigidity, or postural instability [63]. A recently approved imaging test called a DaTscan uses a radiopharmaceutical dopamine transporter (DaT) and single photon emission computerized tomography (SPECT) to assist in the diagnosis of patients with Parkinson symptoms by revealing decreased dopamine transporter function in patients with PD. However, because it cannot differentiate between PD and Parkinsonian syndrome (PS), the levodopa and apomorphine challenge tests are used to differentiate PD from PS [63]. Gao and colleagues found that USE performed in patients suspected to have PD or PS showed significant results when correlated with the acute levodopa challenge test and the Unified Parkinson's Disease Rating Scale (UPDRS) score [64]. In their study, each patient had their strain ratio (SR) measured by SWE prior to and 60 min after levodopa administration. They found that the difference in SR before and after Levodopa administration was significant in PD (Fig. 6) whereas it was not in PS. Patients diagnosed with PD had an SR p-value of 0.02, patients diagnosed with PS had an SR p-value of 0.14. From this study, it was concluded that USE is a clinically reliable way to quantitatively distinguish PD from PS with the acute levodopa challenge test [64]. SWE is also useful in the assessment of the muscle stiffness in PD. A significant difference in muscle stiffness measured by SWE is observed between the affected muscle and non-affected muscle in PD, as well as between the affected muscle in PD and healthy muscles [57].

3.4. Stroke

A stroke occurs when blood flow to the brain is compromised. If brain cells are deprived of oxygen for a sufficient amount of time, brain function is negatively affected with possible permanent ischemic brain damage. A potential consequence of this damage is muscle spasticity, a combination of paralysis, increased muscle tone and hyperactive reflexes. Spasticity is one of the leading causes of post-stroke disability as over 50% of post-stroke patients undergo rehabilitation for spasticity [65]. Spasticity compromises the patient's ability to perform activities of daily living thus decreasing quality of life. Electromyography (EMG)

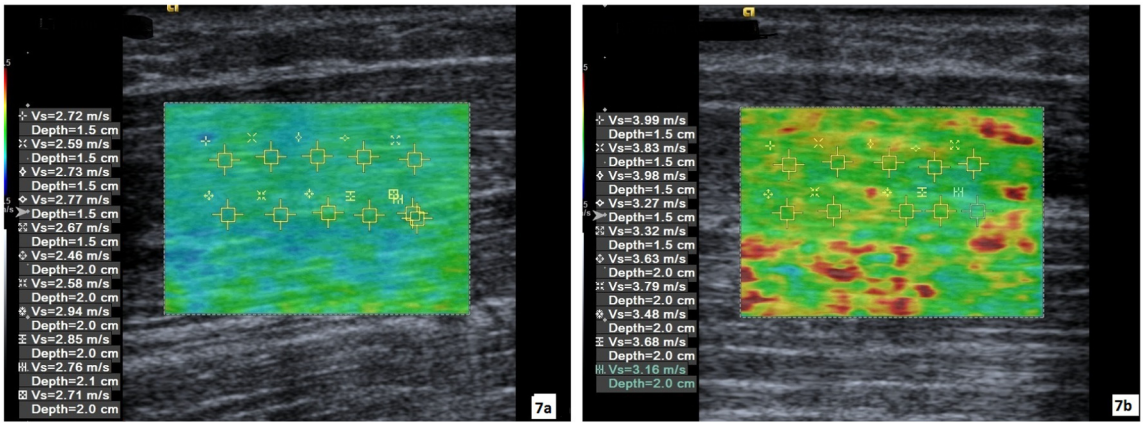

Fig. 7. a–b. Shear wave elastography of bilateral biceps brachii muscles is performed in patients with poststroke spasticity of the upper limb. The difference in shear wave velocity (m/s) representing muscle stiffness between the non-spastic (7a) and spastic (7b) biceps brachii muscles is significant ($p < 0.05$) [65].

has been used to assess spasticity, but surface EMG only assesses superficial muscular electrical activity, and intramuscular EMG is an invasive test that often causes pain and anxiety [65]. Spasticity can be assessed with certain clinical tools, including the Modified Ashworth Scale (MAS) and Tardieu Scale (TS) [66]. In ultrasound applications, spasticity was detected while measuring the shear wave velocity (SWV) in spastic and non-spastic biceps brachii muscle (BBM) of post-stroke patients. It was observed that the spastic biceps muscle was significantly more stiff than the non-spastic BBM with a reported p-value of < 0.0001 [65] and $p = 0.002$ [66] when the elbow was at full extension (Fig. 7). SWV is greater on the post-stroke spastic side in patients that are in the acute and chronic post-stroke stage supporting the hypertonicity and stiffness as aspects of spasticity [65,66]. Monitoring post-stroke spasticity is critical as it is a marker of sensorimotor malfunction and is used for guiding treatment and follow-up. It is known that chronic spasticity can be associated with an increase in connective tissue changes (fibrosis) and an increase of adipose tissue within the muscle [67], but there is no evidence supporting these changes in the acute post-stroke stage [66]. In addition, an increase in muscle stiffness and a decrease in muscle dynamic movement in spasticity can be demonstrated using ultrasound strain elastography [68].

3.5. Multiple sclerosis

MS is a demyelinating disorder of the central nervous system (CNS) that compromises the communication between the CNS and the rest of the body. This type of degenerative damage can also result in the development of stiffness, spasticity, and even paralysis of the extremities. The 0–10 numeric rating score (NRS) is another subjective test that has recently been introduced and appears to improve quality of life compared to MAS but is still a subjective test as patients rate their level of spasticity on a scale of 0–10 [31]. A new score was introduced by Illomei and colleagues that compares the MAS and NRS to USE called the Muscle Elastography Multiple Sclerosis Score (MEMSs), and it was found that MEMSs had a significant Pearson's correlation coefficient when correlated with the MAS with a p-value < 0.001 [31,32]. The evolution of USE applications for MS can give physicians real-time quantitative data on muscle fibers to help diagnose MS and evaluate the response to treatment [31].

4. Limitations and perspectives on currently used ultrasound elastography

There are many compelling reasons why USE is an expanding area of imaging. USE is a fast, non-invasive, and low-cost modality that can be employed easily in many clinical scenarios [37]. As previously reported in our review, spasticity plays a significant role in the burden of disease as well as the decreased function and quality of life experienced by patients with neuromuscular and movement disorders because there is lack of a quantitative method to assess spasticity. Dieleman and colleagues reported that 101.3 billion dollars were spent in 2013 on neurological disorders alone. They also reported that the amount of spending was increasing at a rate of 4% per year for neurological disorders. [5]. Researchers are optimistic that USE will play an expanding role in aiding diagnosis of disease [31,60,64], monitoring disease progression [11,13], assessment of treatment response [11,13,31,66], and assessment of response to rehabilitation [65]. It is hopeful that improvement in these key areas with a low-cost modality will improve patient outcomes by increasing functionality leading to an overall decrease in financial burden.

4.1. Limitations

There are limitations to currently used ultrasound elastography. A majority of the studies to date have been case reports, non-controlled studies, or small studies with few subjects. To fully understand the utility of USE and its sensitivity and specificity, long-term pilot and multi-center studies with a diverse set of subjects are needed [37]. Supplementary studies are also necessary to assess what USE techniques are the most effective and what their limitations are for each individual disorder. Limitations of each technique were explained in their individual sections. However, additional studies comparing the different USE techniques in each disorder are necessary to determine if limitations exist with a corresponding technique and disorder. In addition to the limited development of the techniques themselves, insufficient training and skill development in USE has led to many investigators acquiring suboptimal results [38]. Mastering the concepts and technical skills of USE is challenging due to the multitude of different methods and complexity of the subject matter [15].

4.2. Perspectives

Although there has been significant work and major advances in ultrasound elastography, additional work is needed to better define its many potential uses. Firstly, ultrasound elastography is currently equipped in high-end ultrasound scanners. It would overcome the economic burden if this imaging technique can be used as a screening tool at the bedside in the clinical settings with low-cost [69]; Secondly, the technique of ultrasound elastography for assessing muscle viscosity needs to be developed; Thirdly, the standardization in the use and performing USE based upon user input and manufacturers' expertise would be beneficial in addressing the issues that currently hinder USE and ensure uniformity across studies [37]. The continued advances in the areas of quantitative data analysis, scanning speed, and image

quality are among the reasons [15] this facet of medicine is growing immensely.

5. Conclusion

Ultrasound elastography can be used in a variety of clinical scenarios and continues to show promise for its role in clinical medicine as an efficient, non-invasive modality that can provide quantitative and qualitative information of muscles and other tissues. This technique may be used to aid clinicians in diagnosing, monitoring, and measuring treatment response in patients with a myriad of neuromuscular and movement disorders. However, further research is needed to establish clear guidelines and recommendation for its use and role in the clinical setting.

Acknowledgments

We acknowledge Siemens Medical Solutions and Canon Medical Systems USA for providing USE images.

References

[1] Zorowitz RD, Gillard PJ, Brainin M. Poststroke spasticity: sequelae and burden on stroke survivors and caregivers. Neurology 2013;80:S45–52.
[2] Deenen JC, Horlings CG, Verschuuren JJ, Verbeek AL, van Engelen BG. The epidemiology of neuromuscular disorders: a comprehensive overview of the literature. J Neuromuscul Dis 2015;2:73–85.
[3] Wenning GK, Kiechl S, Seppi K, Muller J, Hogl B, Saletu M, et al. Prevalence of movement disorders in men and women aged 50–89 years (bruneck study cohort): a population-based study. Lancet Neurol 2005;4:815–20.
[4] Ma VY, Chan L, Carruthers KJ. Incidence, prevalence, costs, and impact on disability of common conditions requiring rehabilitation in the United States: stroke, spinal cord injury, traumatic brain injury, multiple sclerosis, osteoarthritis, rheumatoid arthritis, limb loss, and back pain. Arch Phys Med Rehabil 2014;95:986–95.
[5] Dieleman JL, Baral R, Birger M, Bui AL, Bulchis A, Chapin A, et al. US spending on personal health care and public health, 1996–2013. JAMA 2016;316:2627–46.
[6] Larkindale J, Yang W, Hogan PF, Simon CJ, Zhang Y, Jain A, et al. Cost of illness for neuromuscular disease in the United States. Muscle Nerve 2014;49:431–8.
[7] Bilston LE, Tan K. Measurement of passive skeletal muscle mechanical properties in vivo: recent progress, clinical applications, and remaining challenges. Ann Biomed Eng 2015;43:261–73.
[8] Biology, eighth edition (Raven). Philosophy of education. https://highered.mheducation.com/sites/9834092339/student_view0/chapter47/action_potentials_and_muscle_contraction.html, Accessed date: 4 May 2018.
[9] Motor units and muscle receptors (section 3, chapter 1) neuroscience online: an electronic textbook for the neurosciences|Department of Neurobiology and Anatomy - The University of Texas Medical School at Houston. Basal Ganglia (section 3, chapter 4). https://nba.uth.tmc.edu/neuroscience/s3/chapter01.html, Accessed date: 4 May 2018.
[10] Condliffe EG, Clark DJ, Patten C. Reliability of elbow stretch reflex assessment in chronic post-stroke hemiparesis. Clin Neurophysiol 2005;116:1870–8.
[11] Brandenburg JE, Eby SF, Song P, Kingsley-Berg S, Bamlet W, Sieck GC, et al. Quantifying passive muscle stiffness in children with and without cerebral palsy using ultrasound shear wave elastography. Dev Med Child Neurol 2016;58:1288–94.
[12] Brandenburg JE, Eby SF, Song P, Zhao H, Brault JS, Chen S, et al. Ultrasound elastography: the new frontier in direct measurement of muscle stiffness. Arch Phys Med Rehabil 2014;95:2207–19.
[13] Gao J, Li PC, Chen J, He W, Du LJ, Min R, et al. Ultrasound strain imaging in assessment of biceps muscle stiffness and dynamic motion in healthy adults. Ultrasound Med Biol 2017;43:1729–36.
[14] Ophir J, Alam SK, Garra B, Kallel F, Konofagou E, Krouskop T, et al. Elastography: ultrasonic estimation and imaging of the elastic properties of tissues. Proc Inst Mech Eng H 1999;213:203–33.
[15] Bamber J, Cosgrove D, Dietrich CF, Fromageau J, Bojunga J, Calliada F, et al. EFSUMB guidelines and recommendations on the clinical use of ultrasound elastography. Part 1: basic principles and technology. Ultraschall Med 2013;34:169–84.
[16] Nightingale K, McAleavey S, Trahey G. Shear-wave generation using acoustic radiation force: in vivo and ex vivo results. Ultrasound Med Biol 2003;29:1715–23.
[17] Sarvazyan AP, Rudenko OV, Swanson SD, Fowlkes JB, Emelianov SY. Shear wave elasticity imaging: a new ultrasonic technology of medical diagnostics. Ultrasound Med Biol 1998;24:1419–35.
[18] Sandrin L, Tanter M, Gennisson JL, Catheline S, Fink M. Shear elasticity probe for soft tissues with 1-D transient elastography. IEEE Trans Ultrason Ferroelectr Freq Control 2002;49:436–46.
[19] Wu Z, Taylor LS, Rubens DJ, Parker KJ. Sonoelastographic imaging of interference patterns for estimation of the shear velocity of homogeneous biomaterials. Phys Med Biol 2004;49:911–22.
[20] Shiina T, Nitta N, Ueno E, Bamber JC. Real time tissue elasticity imaging using the combined autocorrelation method. J Med Ultrason 2002;29:119–28.
[21] Klauser AS, Miyamoto H, Bellmann-Weiler R, Feuchtner GM, Wick MC, Jaschke WR. Sonoelastography: musculoskeletal applications. Radiology 2014;272:622–33.
[22] Friedrich-Rust M, Ong MF, Martens S, Sarrazin C, Bojunga J, Zeuzem S, et al. Performance of transient elastography for the staging of liver fibrosis: a meta-analysis. Gastroenterology 2008;134:960–74.
[23] Li Z, Du L, Wang F, Luo X. Assessment of the arterial stiffness in patients with acute ischemic stroke using longitudinal elasticity modulus measurements obtained with shear wave elastography. Med Ultrason 2016;18:182–9.
[24] Itoh A, Ueno E, Tohno E, Kamma H, Takahashi H, Shiina T, et al. Breast disease: clinical application of US elastography for diagnosis. Radiology 2006;239:341–50.
[25] Dighe M, Luo S, Cuevas C, Kim Y. Efficacy of thyroid ultrasound elastography in differential diagnosis of small thyroid nodules. Eur J Radiol 2013;82:e274–80.
[26] Pallwein L, Mitterberger M, Struve P, Pinggera G, Horninger W, Bartsch G, et al. Real-time elastography for detecting prostate cancer: preliminary experience. Br J Urol 2007;100:42–6.
[27] Thomas A, Kummel S, Gemeinhardt O, Fischer T. Real-time sonoelastography of the cervix: tissue elasticity of the normal and abnormal cervix. Acad Radiol 2007;14:193–200.
[28] Janssen J, Schlorer E, Greiner L. EUS elastography of the pancreas: feasibility and pattern description of the normal pancreas, chronic pancreatitis, and focal pancreatic lesions. Gastrointest Endosc 2007;65:971–8.
[29] De Zordo T, Chhem R, Smekal V, Feuchtner G, Reindl M, Fink C, et al. Real-time sonoelastography: findings in patients with symptomatic Achilles tendons and comparison to healthy volunteers. Ultraschall Med 2010;31:394–400.
[30] Shiina T, Nightingale KR, Palmeri ML, Hall TJ, Bamber JC, Barr RG, et al. WFUMB guidelines and recommendations for clinical use of ultrasound elastography: part 1: basic principles and terminology. Ultrasound Med Biol 2015;41:1126–47.
[31] Illomei G. Muscle elastography in multiple sclerosis spasticity. Neurodegener Dis Manag 2016;6:13–6.
[32] Illomei G, Spinicci G, Locci E, Marrosu MG. Muscle elastography: a new imaging technique for multiple sclerosis spasticity measurement. Neurol Sci 2017;38:433–9.
[33] Li Y, Snedeker JG. Elastography: Modality-specific Approaches, Clinical Applications, and Research Horizons. 40. 2010. p. 389–97.
[34] Ophir J, Cespedes I, Ponnekanti H, Yazdi Y, Li X. Elastography: a quantitative method for imaging the elasticity of biological tissues. Ultrason Imaging 1991;13:111–34.
[35] Lubinski MA, Emelianov SY, O'Donnell M. speckle tracking methods for ultrasonic elasticity imaging using short-time correlation. IEEE Trans Ultrason Ferroelectr Freq Control 1999;46:82–9.
[36] O'Donnell M, Skovoroda AR, Shapo BM, Emelianov SV. Internal displacement and strain imaging using ultrasound speckle tracking. IEEE Trans Ultrason Ferroelectr Freq Control 1994;41:314–25.
[37] Drakonaki EE, Allen GM, Wilson DJ. Ultrasound elastography for musculoskeletal applications. Br J Radiol 2012;85:1435–45.
[38] Garra BS. Elastography: history, principles, and technique comparison. Abdom Imaging 2015;40:680–97.
[39] Carlsen JF, Ewertsen C, Lonn L, Nielsen MB. Strain elastography ultrasound: an overview with emphasis on breast cancer diagnosis. Diagnostics 2013;3:117–25.
[40] Yerli H, Yilmaz T, Kaskati T, Gulay H. Qualitative and semiquantitative evaluations of solid breast lesions by sonoelastography. J Ultrasound Med 2011;30:179–86.
[41] Xu JP, Tripathy S, Rubin JM, Stidham R, Johnson LA, Higgins PD, et al. A new nonlinear parameter in the developed strain-to-applied strain of the soft tissues and its application in ultrasound elasticity imaging. Ultrasound Med Biol 2012;38:511–23.
[42] De Zordo T, Fink C, Feuchtner GM, Smekal V, Reindl M, Klauser AS. Real-time sonoelastography findings in healthy Achilles tendons. Am J Roentgenol 2009;193:W134–8.
[43] Bhatia KSS, Rasalkar DD, Lee YP, Wong KT, King AD, Yuen YH, et al. Real-time qualitative ultrasound elastography of miscellaneous non-nodal neck masses: applications and limitations. Ultrasound Med Biol 2010;36:1644–52.
[44] Sigrist RMS, Liau J, Kaffas AE, Chammas MC, Willmann JK. Ultrasound elastography; review of techniques and clinical applications. Theranostics 2017;7:1303–29.
[45] Ophir J, Alam SK, Garra BS, Kallel F, Konofagou EE, Krouskop T, et al. Elastography: imaging the elastic properties of soft tissues with ultrasound. J Med Ultrason 2002;29:155–71.
[46] Varghese T. Quasi-static ultrasound elastography. Ultrasound Clin 2009;4:323–38.
[47] Nightingale K, Soo MS, Nightingale R, Trahey G. Acoustic radiation force impulse imaging: in vivo demonstration of clinical feasibility. Ultrasound Med Biol 2002;28:227–35.
[48] Eby SF, Song P, Chen S, Chen Q, Greenleaf JF, An KN. Validation of shear wave elastography in skeletal muscle. J Biomech 2013;46:2381–7.
[49] Cosgrove DO, Berg WA, Dore CJ, Skyba DM, Henry JP, Gay J, et al. Shear wave elastography for breast masses is highly reproducible. Eur Radiol 2012;22:1023–32.
[50] Arda K, Ciledag N, Aktas E, Aribas BK, Kose K. Quantitative assessment of normal soft-tissue elasticity using shear-wave ultrasound elastography. Am J Roentgenol 2011;197:532–6.
[51] Ferraioli G, Parekh P, Levitov AB, Filice C. Shear wave elastography for evaluation of liver fibrosis. J Ultrasound Med 2014;33:197–203.
[52] Bercoff J, Tanter M, Fink M. Supersonic shear imaging: a new technique for soft tissue elasticity mapping. IEEE Trans Ultrason Ferroelectr Freq Control 2004;51:396–409.
[53] Aubry S, Nueffer JP, Carrie M. Evaluation of the effect of an anisotropic medium on shear wave velocities of intra-muscular gelatinous inclusion. Ultrasound Med Biol 2017;43:301–8.

[54] Gennisson JL, Deffieux T, Mace E, Montaldo G, Fink M, Tanter M. Viscoelastic anisotropic mechanical properties of in vivo muscle tissue assessed by supersonic shear imaging. Ultrasound Med Biol 2010;36:789–801.
[55] Eby SF, Cloud BA, Brandenburg JE, Giambini H, Song P, Chen S, et al. Shear wave elastography of passive skeletal muscle stiffness: influences of sex and age throughout adulthood. Clin Biomech 2015;30:22–7.
[56] Chen J, O'Dell M, He W, Du LJ, Li PC, Gao J. Ultrasound shear wave elastography in the assessment of passive biceps brachii muscle stiffness: influences of sex and elbow position. Clin Imaging 2017;45:26–9.
[57] Du LJ, He W, Cheng LG, Li S, Pan YS, Gao J. Ultrasound shear wave elastography of muscle stiffness in patients with Parkinson's disease: a primary observation. Clin Imaging 2016;40:1075–80.
[58] Friedrich-Rust M, Wunder K, Kriener S, Sotoudeh F, Richter S, Bojunga J, et al. Liver fibrosis in viral hepatitis; noninvasive assessment with acoustic radiation force impulse imaging versus transient elastography. Radiology 2009;252:595–604.
[59] Sporea I, Lie I. Shear wave elastography. Ultraschall Med 2012;33:393–4.
[60] Botar-Jid C, Damian L, Dudea SM, Vasilescu D, Rednic S, Badea R. The contribution of ultrasonography and sonoelastography in assessment of myositis. Med Ultrason 2010;12:120–6.
[61] Lee SS, Gaebler-Spira D, Zhang LQ, Rymer WZ, Steele KM. Use of shear wave ultrasound elastography to quantify muscle properties in cerebral palsy. Clin Biomech 2016;31:20–8.
[62] Bilgici MC, Becki T, Ulus Y, Ozyurek H, Adydin OF, Tomak L, et al. Quantitative assessment of muscle stiffness in children with cerebral palsy using acoustic radiation impulse (ARFI) ultrasound elastography. J Med Ultrason 2018;45:295–300.
[63] Jankovic J. Parkinson's disease: clinical features and diagnosis. J Neurol Neurosurg Psychiatry 2008;79:368–76.
[64] Gao J, Du LJ, He W, Li S, Cheng LG. Ultrasound strain elastography in assessment of muscle stiffness in acute levodopa challenge test: a feasibility study. Ultrasound Med Biol 2016;42:1084–9.
[65] Gao J, He W, Du LJ, Chen J, Park D, Wells M, et al. Quantitative ultrasound imaging to assess the biceps brachii muscle in chronic post-stroke spasticity: preliminary observation. Ultrasound Med Biol 2018;44:1931–40.
[66] Wu CH, Ho YC, Hsiao MY, Chen WS, Wang TG. Evaluation of post-stroke spasticity muscle stiffness using shear wave ultrasound elastography. Ultrasound Med Biol 2017;43:1105–11.
[67] Lieber RL, Ward SR. Cellular mechanisms of tissue fibrosis: 4. Structural and functional consequences of skeletal muscle fibrosis. Am J Phys Cell Phys 2013;305:C241–52.
[68] Gao J, Chen J, O'Dell M, Li PC, He W, Du LJ, et al. Ultrasound strain imaging to assess the biceps brachii muscle in chronic poststroke spasticity. J Ultrasound Med 2018;37:2043–52.
[69] Simon NG, Noto YI, Zaidman CM. Skeletal muscle imaging in neuromuscular disease. J Clin Neurosci 2016;33:1–10.